

## Case Report

# ACUTE DIVERTICULITIS OF THE APPENDIX: A CASE REPORT

## DIVERTICULITIS APENDICULAR AGUDA: REPORTE DE CASO

Manuel Cadena<sup>1</sup>, Roció López<sup>2</sup>, Linda Cardoso<sup>3</sup>, Luis Felipe Cabrera-Vargas<sup>1,4</sup>, Danae García<sup>3</sup>, Daniela Velásquez-Candamil<sup>5</sup>, Ivan David Lozada-Martínez<sup>6,7\*</sup>

<sup>1</sup>Department of Surgery, Fundación Santa Fé, Bogotá, Colombia

<sup>2</sup>Departement of Pathology, Fundación Sante Fé, Bogotá, Colombia

<sup>3</sup>School of Medicine, Universidad de los Andes, Bogotá, Colombia

<sup>4</sup>Department of Surgery, Universidad El Bosque, Bogotá, Colombia

<sup>5</sup>Semillero de Investigación en Ciencias Médicas Quirúrgicas, School of Medicine, Institución Universitaria Visión de las Américas, Pereira, Colombia

<sup>6</sup>Medical and Surgical Research Center, Future Surgeons Chapter, Colombian Surgery Association, Bogotá, Colombia

<sup>7</sup>International Coalition on Surgical Research, Universidad Nacional Autónoma de Nicaragua, Managua, Nicaragua

### \*Corresponding Author:

Ivan David Lozada-Martínez

Medical and Surgical Research Center, Future Surgeons Chapter,  
Colombian Surgery Association, Bogotá, Colombia.

Email: [ilozadam@unicartagena.edu.co](mailto:ilozadam@unicartagena.edu.co)

Received: 5 May 2023. Approved: 21 July 2023. Published: November 2023

### Abstract

Appendicular diverticulitis is a rare condition that can simulate acute appendicitis, it has an incidence ranging from 0.004 to 2.1%. It presents a higher rate of perforation, mortality, and association with appendicular neoplasms. We present a case of a 42-year-old male presented in the emergency room with clinical signs of acute appendicitis, laparoscopic appendectomy was indicated. Intraoperative findings of diverticulum of cecum appendix, laparoscopic appendectomy was accomplished. Diverticulitis of the appendix is a rare pathology. Appendectomy is the gold standard treatment either laparoscopic or open approach.

## Resumen

La diverticulitis apendicular es una condición rara que puede simular una apendicitis aguda, tiene una incidencia que oscila entre el 0,004 y el 2,1%. Presenta una mayor tasa de perforación, mortalidad y asociación con neoplasias apendiculares. Se presenta el caso de un varón de 42 años que se presenta en urgencias con signos clínicos de apendicitis aguda, indicándosele apendicectomía laparoscópica. Se encontró un divertículo en el apéndice del ciego, por lo que se realiza resección laparoscópica. La diverticulitis del apéndice es una patología rara. La apendicectomía es el tratamiento de referencia, ya sea por vía laparoscópica o abierta.

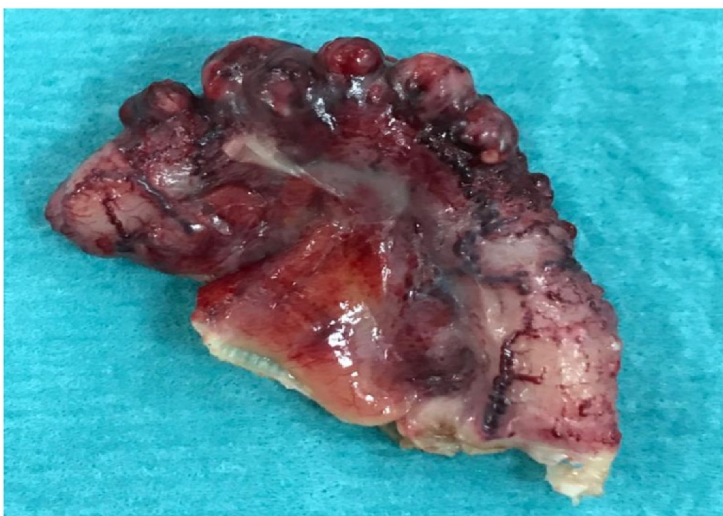
**Keywords:** Wounds And Injuries, Hospital Rapid Response Team, Patient Care Team, Surgery.

## Introducción

Appendicitis is one of the most common surgical emergencies in contemporary medicine with an incidence of 100 cases per 100,000 habitants [1-3]. Appendicular diverticulitis is a rare condition that can mimic acute appendicitis, this condition was initially described in 1893 by Kelynnack as a widely distended, completely sealed appendix of the cecum [4]. It has an incidence ranging from 0.004 to 2.1% and appears to be more frequent in men and patients with cystic fibrosis and a history of Hirschsprung's disease [5]. Considering the unusual presentation of these cases, and with the aim of contributing to the clinical and academic memory of appendiceal diverticulitis, this case report is presented. This case report followed the CARE guidelines for its realization [6].

## Case report

A 42-year-old male patient with no previous medical history related to his current condition, Attends the Fundación Santa Fe's Emergency Department in Bogotá. He was admitted for presenting abdominal pain in the right inferior quadrant of progressive intensity, fever, and hyporexia of 3 days of evolution. Physical exam showed vital signs within normal limits, abdominal pain in the right inferior quadrant, with positive Blumberg and Psoas signs. The white blood cell count was 13,600 with 10,600 neutrophils. The presumptive preoperative diagnosis was acute appendicitis with an Alvarado's test of 8. Laparoscopic appendectomy was indicated. During the surgical procedure, the surgeon found acute appendicitis with the presence of diverticular formations in the appendix with inflammatory changes, without macroscopic perforation (Figure 1).



*Figura 1. Surgical specimen removed by laparoscopy, an irregular external surface, congestive vessels, with fibrin membranes, no macroscopic perforation of any diverticulum.*

The histopathological study showed a cecal appendix measuring 4.7 cm x 0.8 cm. In which it

showed several lesions of diverticular aspects, in some the muscular layer partially conserved (Figure 2 A-B).

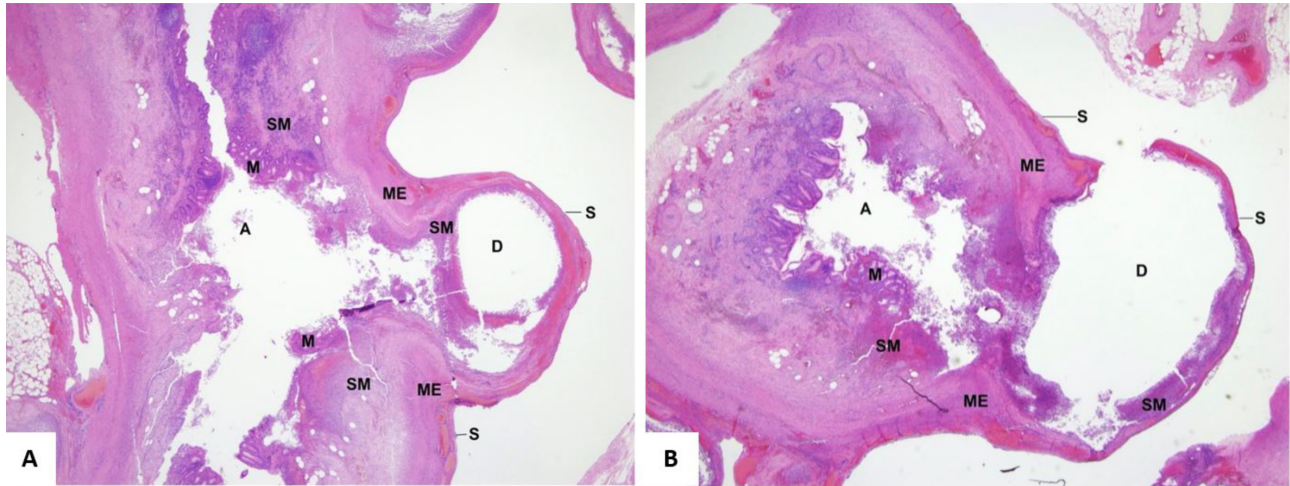


Figure 2. A. Longitudinal section of the cecal appendix with pseudodiverticulum in hematoxylin-eosin stain. B. Cross-section of the cecal appendix with pseudodiverticulum in hematoxylin-eosin stain. A: lumen of the appendix, D: lumen of the pseudodiverticulum, M: mucosa, EM: external muscularis, S: serosa, SM: submucosa.

However, with actin an immunomarker, it showed that the continuity of the external muscular is extensively compromised, the eroded submucosa is invaginated (from the inflammation of acute suppurative

appendicitis) creating a diverticulum (Figure 3). The patient had an adequate postoperative evolution, tolerated oral intake in two hours and was discharged without complications.

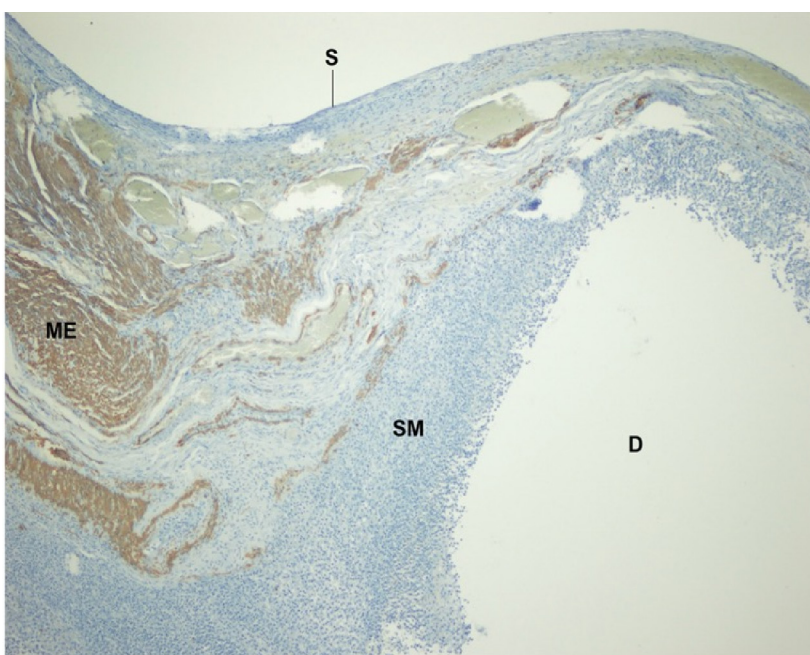


Figure 3. Cross-section of the cecal appendix with pseudodiverticulum in immunostaining actin marker.



## Discussion

The pathogenesis of this condition is not truly known, but several explanations have been provided. The inflammatory theory [8-15] proposes that acute inflammation of the appendix weakens the walls, with subsequent ulceration and regeneration of the damaged epithelium. Stout et al, on the other hand, proposed in 1923 that a combination between luminal obstruction and accumulation of secretions produced by the appendix (1-2 ml daily), added to the muscular contraction of the appendix leads to a herniation of the mucous layer producing the diverticula [1,9]. It is necessary to highlight the difference between pseudodiverticulum and true diverticulum, pseudodiverticula involve only mucosa and serosa while true

diverticula (Meckel's diverticula) involve muscular, serosa and mucosa. Theoretically, this finding would be concise in pseudodiverticulum. The presentation of appendicular diverticulitis mimics acute appendicitis [12], therefore most cases are diagnosed during the anatomopathological study [7,11,15], as in our case. Moreover, it should be considered that it is more prevalent in men [6,7] in their fifth decade of life [1]. For appendicular diverticulitis, there are multiple risk factors like older age, male gender, Hirschsprung's disease and cystic fibrosis [6,8].

The clinical presentation is acute abdominal pain in the right lower quadrant. Nonetheless, this can be of two types acute or chronic, that can endure between 7 and 12 days. The presentation will depend on the type of diverticular disease as shown in Table 1 [17].

Table 1. Classification of appendicular diverticulitis [17]

Type	Classification
1	Primary acute appendicitis, with or without acute peri-diverticulitis
2	Acute diverticulitis secondary to acute appendicitis
3	Diverticulum without inflammation
4	Diverticulum with acute appendicitis
5	Chronic peri-diverticulitis with acute appendicitis

Type 1 is characterized by an intermittent, insidious pain of longer duration weeks, months even years, nevertheless, most of the cases are asymptomatic [4]. On the other hand, the clinical presentation of type 2, 4 and 5 consist of a typical presentation of acute appendicitis, but unlike it, it usually is not associated with gastrointestinal symptoms or systemic inflammatory response [3]. However, if complications occur [6], patients may develop these symptoms, as in our case that was type 2. Finally, type 3 is asymptomatic [3].

As for imaging studies, computed tomography has a sensitivity and specificity of up to 80 and 100% respectively [5,8,11]. In this technique, it is possible to visualize inflamed diverticula with an increase of the contrast in the wall of the diverticulum. Nevertheless, the knowledge of the operator is vital for an earlier diagnosis of this condition [5]. Also,

some authors argue that it is possible to make a diagnosis with ultrasound [14] by finding an increase in the thickness of the appendicular wall and an increase in the echogenicity due to the presence of air [4,8,11,14]. However, in our case, no diagnostic image was used since the clinical presentation was conclusive for acute appendicitis. On the other hand, it has been seen that this pathology carries a higher risk of perforation (66% of the cases), of mortality (30% more than in acute appendicitis) and higher risk of malignancy (7.1% to 48% of the cases) mainly of mucinous adenoma [1,6,15,16]. Histopathological analysis should be considered if available, since appendiceal diverticulitis has also been associated with carcinoid tumors [18]. It is thought to be due to a longer time of inflammation in the appendicular mucosa, since the diagnosis is made late, due to the non-specific symptomatology and the absence of a thick

muscular wall<sup>1</sup>. Its treatment is laparoscopic or open appendectomy as in acute appendicitis [2]. If it is detected as an incidental finding in a diagnostic image, prophylactic appendectomy is recommended even in the absence of inflammatory signs [5,10].

## Conclusion

In conclusion, appendicular diverticulitis is a rare pathology that simulates acute appendicitis and tends to be an incidental diagnosis in anatomopathological studies. It is of crucial importance to consider it within the differential diagnoses since it presents a higher rate of perforation, mortality, and association with appendicular neoplasms. The treatment is surgical with laparoscopic appendectomy or open surgery if there is no availability. It can be either therapeutically or prophylactically if it is an incidental diagnosis in asymptomatic patients.

## Author Statements

- Conflict of Interest: the authors declare that they have no conflict of interest.
- Funding Sources: This article has not received specific support from public sector agencies, the commercial sector or non-profit entities.

## Referencias

1. Sohn TJ, Chang YS, Kang JH, et al. Clinical characteristics of acute appendiceal diverticulitis. *J Korean Surg Soc.* 2013; 84(1):33-7.
2. Abdulmomen AA, AlZahrani AS, Al Mulla LA, Alaqeel FO. Acute Perforated Appendicitis Associated with Appendiceal Diverticulitis in a Young Man: A Case Report with Literature Review. *Am J Case Rep.* 2022; 23:e934838.
3. Brunnicardi FC, et al. The Appendix. *Schwartz's principles of surgery.* Liang MK, Andersson RE, Jaffe BM, Berger McGraw-Hill DH Education. 10th ed. 2015; 30:1241-1245.
4. Escobar F, Vega NV, Valbuena E, Baron M. Appendiceal diverticulitis, literature review and presentation of two cases. *Rev Colomb Cir.* 2013; 28(3):223-228.
5. Altieri ML, Piozzi GN, Salvatori P, Mirra M, Piccolo G, Olivari N. Appendiceal diverticulitis, a rare relevant pathology: Presentation of a case report and review of the literature. *Int J Surg Case Rep.* 2017; 33:31-34.
6. Riley DS, Barber MS, Kienle GS, et al. CARE guidelines for case reports: explanation and elaboration document. *J Clin Epidemiol.* 2017; 89:218-235.
7. Ergenç M, Uprak TK. Appendiceal Diverticulitis Presenting as Acute Appendicitis and Diagnosed After Appendectomy. *Cureus.* 2022; 14(3):e23050.
8. Moayerifar M, Torabi H, Shirini K, Ashoorian Y. A rare simultaneous occurrence of appendiceal diverticulitis and non-perforated peptic ulcer mimicking abdominal peritonitis symptoms. *Clin Case Rep.* 2022; 10(4):e05780.
9. Bujold-Pitre K, Mailloux O. Diverticulitis of the appendix-case report and literature review. *J Surg Case Rep.* 2021; 2021(10):rjab488.
10. Souferi B, Sheppard K, Onayemi AO, Davis JM. Incidental Findings of Appendiceal Diverticulitis Presenting as Acute Appendicitis. *Am Surg.* 2022; 88(5):1008-1010.
11. Yardimci AH, Bektas CT, Pasaoglu E, et al. Retrospective study of 24 cases of acute appendiceal diverticulitis: CT findings and pathological correlations. *Jpn J Radiol.* 2017; 35(5):225-232.
12. Hammad Alam SM. Appendicular Diverticulosis with Appendicitis. *J Coll Physicians Surg Pak.* 2017; 27(3):183-184.
13. Vass T, Zaránd A, Horányi D, Harsányi L. Diverticulosis and diverticulitis of the vermiform appendix. Report of a case and review of the literature. *Orv Hetil.* 2018; 159(19):768-772.
14. Albeeshi MZ, Alwanyan AA, Salim AA, Albabtain IT. Appendiceal diverticulitis presenting as acute appendicitis diagnosed postoperatively. *J Surg Case Rep.* 2019; 2019(12):rjz332.
15. Onafowokan OO, Khairat A, Bonatti HJR. Appendiceal Diverticulitis in a Young Female Diagnosed on Pathology after Laparoscopic Appendectomy for Acute Appendicitis. *Case Rep Med.* 2021; 2021:2508956.
16. Williams JM, Adamo DA, Olson MC. Acute appendiceal diverticulitis: a case report. *Radiol Case Rep.* 2021; 16(5):1072-1074.

17. Phillips BJ. Appendiceal diverticulitis. Mayo Clin Proc. 1999; 74(9):890-2.
18. Kim S, Makkapati S, Modukuru V, Wallack M. A rare triad of appendiceal diverticula, appendiceal carcinoid, and colonic diverticula. SAGE Open Med Case Rep. 2022; 10:2050313X221106005.