

Original article

SYSTEMIC CHEMOTHERAPY IN APPENDICEAL ADENOCARCINOMAS WITH PERITONEAL METASTASES. IS IT WORTH IT?

QUIMIOTERAPIA SISTÉMICA EN ADENOCARCINOMAS APENDICULARES CON METÁSTASIS PERITONEALES. ¿VALE LA PENA?

Francisco J. Morera-Ocón^{1*}; Bruno Camps-Vilata²

¹Hospital General de Requena, Valencia, General Surgery, Spain.

²Hospital Clínico Universitario de Valencia, General Surgery, Spain; and Universitat de València, Facultad de Medicina y Odontología, Valencia, Spain

***Corresponding Author:**

Hospital Clinico Universitario de Valencia.
Avenida Blasco Ibañez, 17. 46010, Valencia, Spain.
Phone: +34 961973500.
Email: fmoreraocon@aecirujanos.es

Received: 14 September 2018, Approved: 02 October 2018, Published: March 2019

Abstract:

Introduction: The role of systemic chemotherapy (SC) in the management of metastatic appendiceal adenocarcinomas is not defined.

Methods: We perform an observational study of patients treated of peritoneal metastases from appendiceal neoplasm between June 2004 and December 2017. They were referred to our hospital for cytoreductive surgery (CRS) with hyperthermic intraperitoneal chemotherapy (HIPEC). Systemic Chemotherapy regimens were decided by the referring oncologist. We analyze Peritoneal Carinomatosis Index (PCI), Completeness of Cytoreduction Score (CC), and use of SC. Overall survival (OS) and progression free survival (PFS) were compared attending to histologic subtype (high- and low-grade adenocarcinomas) and the use of SC.

Results: 60 patients were included, 26 were male, median age 63 years (26-81). Median follow-up of 38 months (2-155). The predominant histologic subtype was mucinous adenocarcinoma (58/60), one was colonic type, and omne adenocarcinoid with signet ring cells. Four patients had extraperitoneal metastases, two hepatic metastases (1 with high-grade mucinous adenocarcinoma and 1 with colonic adenocarcinoma), and two in the low-grade group developed parenchymal lung disease. Three patients died in the postoperative period. Systemic chemotherapy was administered in 26 patients of 57. No difference were observed in the OS and PFS regardless the use of SC in the high- and in the lo-grade groups.

Conclusions: The use of SC in low-grade mucinous adenocarcinoma subtype is not supported by our results, and there is no literature date supporting it neither. Palliative SC in high-grade patients deserves of clinical trials for been accepted as standard of care, when benefits are not clearly established by evidence and toxicities are not negligible.

Resumen:

Introducción: El rol de la quimioterapia sistémica (QS) en el tratamiento de los adenocarcinomas apendiculares metastásicos no está definido.

Métodos: Realizamos un estudio observacional de pacientes tratados con metástasis peritoneales de neoplasma apendicular entre junio de 2004 y diciembre de 2017. Fueron remitidos a nuestro hospital para Cirugía citorreductora (CRS) con quimioterapia intraperitoneal hipertermica (HIPEC). Los regímenes de quimioterapia sistémica fueron decididos por el oncólogo referente. Analizamos índice de carcinomatosis peritoneal (PCI), la puntuación de citorreducción completa (CC) y el uso de SC. La supervivencia global (OS) y la supervivencia libre de enfermedad (PFS) se compararon atendiendo al subtipo histológico (adenocarcinomas de grado alto y bajo) y al uso de SC.

Resultados: Se incluyeron 60 pacientes, 26 hombres, mediana de edad 63 años (26-81). Mediana de seguimiento de 38 meses (2-155). El subtipo histológico predominante fue el adenocarcinoma mucinoso (58/60), uno fue de tipo colónico y un adenocarcinoma con células en anillo de sello. Cuatro pacientes tuvieron metástasis extraperitoneales, dos metástasis hepáticas (1 con adenocarcinoma mucinoso de alto grado y 1 con adenocarcinoma de colon), y dos en el grupo de bajo grado desarrollaron enfermedad pulmonar parenquimatosa. Tres pacientes fallecieron en el postoperatorio. Se administró quimioterapia sistémica en 26 pacientes de 57. No se observaron diferencias en el sistema operativo y PFS, independientemente del uso de SC en los grupos de grado alto y bajo.

Conclusiones: El uso de SC en el subtipo de adenocarcinoma mucinoso de bajo grado no está respaldado por nuestros resultados, y no hay datos publicados que lo respalden. El SC paliativo en pacientes de alto grado merece los ensayos clínicos por haber sido aceptado como un estándar de atención, cuando los beneficios no están claramente establecidos por la evidencia y las toxicidades no son despreciables.

Keywords: Appendiceal Neoplasms, Chemotherapy, Cancer, Regional Perfusion, Hypertermia Induced.

Introduction

Appendiceal epithelial neoplasms are divided broadly into three histologic types, mucinous, non-mucinous, and carcinoids. Mucinous appendiceal neoplasms demonstrate a metastatic site predilection for the peritoneum, with systemic distant targets such as liver or lung being extremely rare. The majority of metastatic mucinous appendiceal adenocarcinomas display slow-growing biology and given the predilection for peritoneum, the primary treatment for those patients is complete cytoreductive surgery followed by hyperthermic intraperitoneal chemotherapy (CRS HIPEC) [1]. Slow-growing appendiceal neoplasms may be considered chemoresistant because of their low proliferation index and their abundant component of acellular mucinous deposits in most of the cases.

The role of systemic chemotherapy (SC) in the management of metastatic appendiceal adenocarcinomas is not clearly defined. Adjuvant SC is often given to patients with poor prognostic factors such as incomplete cytoreduction, high-grade subtype, and lymph node involvement. Nevertheless, the efficacy of adjuvant postoperative chemotherapy in patients with appendiceal neoplasms is unknown

[2].

The role of adjuvant SC in low-grade appendiceal adenocarcinomas is less studied in medical literature, and the indication for chemotherapy drugs in patients harboring this histologic type is ill-defined [3].

Systemic chemotherapy has been utilized in patients with appendiceal epithelial neoplasms who are not candidates for surgical cytoreduction, no matter the histological grade was [4]. Given the indolent course of the disease in the majority of appendiceal mucinous peritoneal carcinomatosis it is of the utmost importance to identify patients who will benefit from adjuvant treatment and those who can be spared the not negligible SC toxicity.

The aim of this study was to analyze the use of systemic chemotherapy in patients with peritoneal metastatic disease from appendiceal epithelial neoplasm treated in our institution with CRS and HIPEC.

Material and methods

We performed a retrospective review of patients

with peritoneal dissemination from appendiceal origin evaluated at the Hospital Clínico Universitario de Valencia between June 2004 and December 2017. This retrospective study was approved by the local review board. Informed consent was obtained from every patient before surgical treatment.

Patients included in the study had histological confirmation of adenocarcinoma of appendiceal origin, and peritoneal involvement from appendiceal neoplasm treated with CRS HIPEC. Most of the patients were referred to our hospital from outside centers.

Patients were explored via midline incision, and resection of involved peritoneal surfaces and organs was performed with peritonectomy procedures. Only sites with apparent disease were resected. The omentum and round ligament of the liver were routinely removed, but not so to the gallbladder. Metastatic dissemination was scored following the Peritoneal Carinomatosis Index described by Sugarbaker [5], and completeness of surgical resection was graded by Completeness of Cytoreduction Score (CC) [5]. HIPEC was performed employing the coliseum technique, and a heating and redistributing machine was employed for circulation of the drug during 60 minutes in the majority of cases (in the first cases, 90 minutes were the time of administration). The employed agent in all of those cases was Mitomycin C, 15mg/m². Afterward, the perfusate was drained and anastomoses performed during the second time of the procedure.

The histological specimens were classified according to the WHO classification for appendiceal tumors [6]. Anatomopathologic reports from specimens before 2010 were translated to the current WHO classification. Mucinous adenocarcinomas were defined by the presence of >50% of extracellular mucin; signet ring cell adenocarcinomas were defined by the presence of >50% signet ring cells.

The decision to administer SC, just as the choice of chemotherapy regimen, was determined by the referring oncologist. In the majority of the cases, oxaliplatin-based regimen was employed. Chemotherapy was administered as neoadjuvant

chemotherapy when patients received it before the scheduled CRS HIPEC; adjuvant chemotherapy when an established number of cycles were administered after the cytoreduction procedure; and palliative chemotherapy when the disease was deemed non resectable.

Progression-free survival (PFS) and overall survival (OS) were analyzed using the Kaplan-Meier method. For the study population, OS was calculated from the date of cytoreduction surgery to death. The log-rank test was used to calculate the survival difference for categorical variables. The chi-square test and Fisher's exact test were used to assess the relationship between categorical variables. T-test was used to assess differences between means of continuous variables. P values were considered statistically significant when $P < 0.05$.

Results

We identified 60 patients who were available for evaluation. There were 26 male patients, 34 were female. The median age was 63 years (range, 26-81). The median follow-up was 38 months (range, 2-155).

All the neoplasms were of mucinous type with the exception of two, where one was colonic type adenocarcinoma, and one was high-grade adenocarcinoid with signet ring cells. The most common histologic grade was low grade or well differentiated histology (72% of the cases).

The clinical and pathologic characteristics and treatment variables of the study population are summarized in Table 1. PCI values were not statistically different between the high- and low-grade groups, nor was it the attained CC score.

Table 1. Characteristics of study patients (n=60)

Median age (years)	63 [26-81]	
Sex		
Male	26 (43%)	
Female	34 (57%)	
Histologic subtype		
Low-grade mucinous histology	45 (75%)	
High-grade		
Mucinous	5 (8%)	
Signed Ring Cell	8 (13%)	
Colonic typed	1 (2%)	
Adenocarcinoid with signet ring cells	1 (2%)	
PCI		
High-grade	17.3 ± 6.3	
Low-grade	16.0 ± 9.1	p=0,628
Completeness of Cytoreduction (CC)		
High-grade		
CC 0,1	12 /15 (80%)	
Low-grade		
CC 0,1	41 /45 (91%)	p=0,672

Nonperitoneal distant metastases occurred in four patients, one patient had liver metastases from high-grade mucinous appendiceal adenocarcinoma, another had also liver metastases from colonic type appendiceal adenocarcinoma, and two patients had lung metastases from low-grade mucinous adenocarcinoma.

Neoadjuvant SC (oxaliplatin-based regimens) defined as SC cycles administered previously to the scheduled CRS and HIPEC procedure was employed in 7/60 (11,7%) patients, 2 of them corresponding to the group of low-grade histology. Two patients of the mucinous high-grade type, and 2 of the signet ring cells group, also received preoperative SC, as well as the patient with colonic type.

Three patients died during the postoperative period (5% postoperative mortality). Two of them had intra-abdominal hemorrhage and underwent reoperation. One of them was previously treated by intravascular embolization but it resulted in ischemic colitis and sepsis. No active bleeding was detected in the laparotomy in those two cases. One patient died from sepsis and gastrointestinal bleeding leading to reoperation and finally multiorgan failure and death.

Systemic Chemotherapy was administered at any

time after CRS/HIPEC in 26 patients/57 (43%), and adjuvant SC was decided by the referral oncologist in 19 patients/57 (32%) following the cytoreduction. Low-grade patients were submitted to adjuvant SC in 11 over the 42 cases (26%).

Patients with histologic subtype high-grade mucinous adenocarcinoma, signet ring cells adenocarcinoma, colonic adenocarcinoma (n=1), and adenocarcinoid (n=1) were grouped together for Kaplan Meier analysis of survival. No differences in OS and PFS were observed regardless the use of adjuvant SC (Figures 1 and 2).

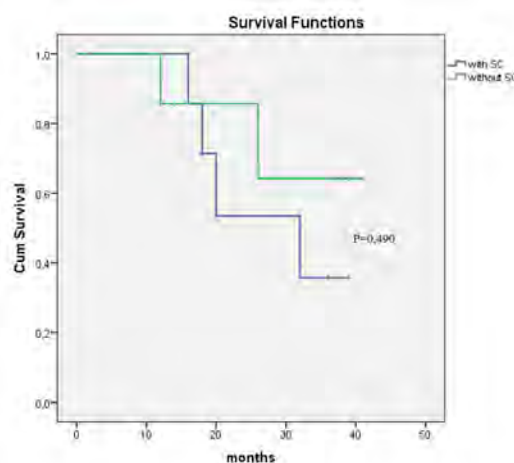


Figure 1. Overall survival in high-grade tumors, with and without systemic chemotherapy (SC)




Figure 2. Progression free survival in high-grade tumors, with and without systemic chemotherapy (SC).

All patients in the low-grade group are alive,

regardless of the use of SC in their follow-up. Not significant differences in the progression free survival were found in the low-grade subtype regardless of SC administration (Figure 3).

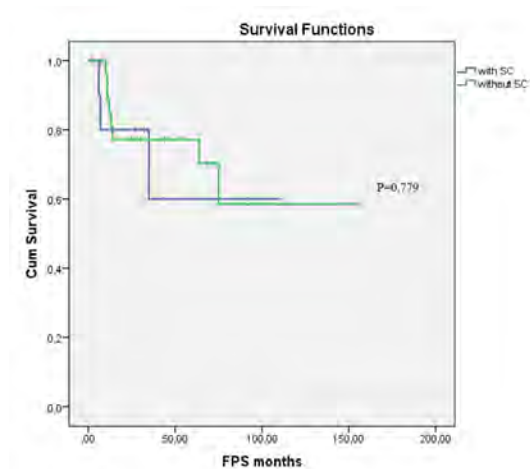


Figure 3. Progression free survival in low-grade lesion group, with and without systemic chemotherapy (SC).

Discussion

It is important to differentiate the histologic type of appendiceal epithelial neoplasm when dealing with a patient diagnosed of metastatic disease. Pseudomyxoma Peritonei (PMP) will be the established diagnosis in some of the patients with appendiceal neoplasm. Nevertheless, PMP is a misnomer which maintains wrong concepts in the field of appendiceal neoplasms research. For example, when it is said that PMP is considered resistant to systemic chemotherapy [7], it is not specified what tumor is it, as the origin of the PMP is appendiceal neoplasm in a large proportion of cases but it can be originated from others tumors such as colonic adenocarcinomas. Even inside the group of appendiceal neoplasms, PMP can be derived from low grade neoplasms but also can be produced by high grade adenocarcinomas of the appendix. Therefore, this terminology cannot be applied as histologic diagnosis for clinical or research purposes [8].

Adenocarcinomas of the appendix are classified into mucinous, nonmucinous, and signet ring cell types[9]. Outcomes are strongly determined by histologic subtype. Generally, mucinous type had the better prognosis, nonmucinous type also known as intestinal or colonic type mimics colon adenocarcinomas, and signet ring cell adenocarcinoma

had the poor prognosis [10].

Historically, patients with low grade appendiceal mucinous neoplasm (LAMN) and pseudomyxoma peritonei had a protracted clinical course with multiple recurrences or persistence of the disease, progressive fibrous adhesions and complications such as fatal obstructive disease when debulking was the treatment of choice. Currently, the standard approach for those neoplasms is performance of CRS and HIPEC [1]. Systemic Chemotherapy has been considered when recurrence occurs. Our data do not support any benefit from SC in those patients, and we agree with Blackham et al. [11] considering repeat CRS and HIPEC the treatment for recurrent or progressive disease, rather than SC, when possible. When cytoreduction is not possible, some oncology providers would consider SC as maintenance treatment. Nevertheless, in a recent analysis of Surveillance, Epidemiology, and Results (SEER) data, patients with stage IV well-differentiated mucinous appendiceal adenocarcinomas demonstrated no benefit from systemic chemotherapy [12]. Taken into account the toxicity of such treatments, we consider that SC has not benefit as maintenance treatment in those patients, and at least dosage of drugs or patterns of administration must be fitted in each individualized patient to reduce the adverse events inherent of this kind of modern regimens.

Even though it is true that low-grade mucinous appendiceal neoplasms demonstrate a relative slow-growing biology and they show poor response to SC, it is not the same for their high-grade or signet ring cell counterpart, which histology appear to have a more aggressive biology, and therefore the potential effects of SC in this subtype of appendiceal neoplasms may be more rewarding. In their retrospective analysis of a large series of poorly differentiated and signed ring cell adenocarcinomas of the appendix, Lieu et al. [13] found that the use of SC for these patients was a valid approach, and that CRS offered a survival benefit in this subgroup of patients mainly in patients in whom CC 0 was achieved. In our present series we have not been able to find significant differences with the use of SC in patients with high-grade histology, but the small size of the sample may bias this result.

Neoadjuvant SC has demonstrated positive results in liver metastases from colorectal origin. Some groups advocate for this modality of treatment

in peritoneal metastases from colorectal origin mimicking the strategy employed in liver metastases, and we support this practice. Nevertheless, conflicting results are reported when neoadjuvant SC is proposed in appendiceal neoplasms [11,14,15]. In the present series, 7 patients received neoadjuvant treatment. Statistical analysis had not been performed in this subgroup of patients because of the limited number of patients. Nevertheless, the descriptive analysis is not useless. The fact that 2 of the 7 patients had low-grade histology revealed the lack of standardization on this topic.

The finding of lung metastases in two patients with low-grade histology in the present series deserves some comments. Malignancy of low-grade appendiceal neoplasms has been questioned. Lymph nodes metastases and distant extraperitoneal metastases are virtually nonexistent, which are arguments to sustain the non-malignant condition of those neoplasm. Nevertheless, in a review article by Kitai [16] in 2012 it was reported 11 cases of true lung metastases from low-grade appendiceal neoplasms. This study included the whole of the cases published until then. We found another case published in 2013 [17] with synchronous lung metastasis from low-grade appendiceal tumor. The existence of two more cases in our series herein presented, and the knowledge of another case communicated in the GECOP (Grupo Español de Cirugía Oncológica Peritoneal) 7th international meeting which was held in Mallorca, (Spain) in 2018, makes a strong argument for the malignancy of low-grade appendiceal neoplasm with extra-appendicular spread, and not to consider this entity as a benign disseminated adenomucinosis with origin in a benign neoplasm of the appendix ruptured to the peritoneum.

The retrospective nature of the current study and the small number of patients included raise the possibility of bias due to lack of power. The unavailability of the oncologic criteria for the prescription of SC in adjuvant regimen diminish the legitimacy of the conclusions of the study. Nevertheless, due to the rarity of appendiceal adenocarcinomas with peritoneal spread the analysis of the series remains of interest in this field, especially when SC studies are lacking.

In conclusion, the indications for SC in advanced appendiceal adenocarcinomas are not delineated. The

use of SC in low-grade mucinous adenocarcinoma subtype is not supported by our results, and there is no literature data supporting this either. The evaluation of the use of SC chemotherapy in the palliative setting in high-grade patients is worthy of a clinical trial before it can be deemed standard of care as it is in colorectal cancer. Nevertheless, simply extrapolate standards of care in colorectal cancer to appendiceal neoplasms seems not justified, as these represent distinct entities with their own biologic behavior: in contrast to colorectal adenocarcinomas, appendiceal neoplasms are commonly mucinous, spread intraperitoneally, and have limited incidence of nodal and systemic metastases.

Disclosures

The authors do not have any conflict of interests about this study.

References

1. Chua TC, Moran BJ, Sugarbaker PH, et al. Early- and long-term outcome data of patients with pseudomyxoma peritonei from appendiceal origin treated by a strategy of cytoreductive surgery and hyperthermic intraperitoneal chemotherapy. *J Clin Oncol* 2012; 30: 2449-2456
2. Tejani MA, ter Veer A, Milne D, et al. Systemic therapy for advanced appendiceal adenocarcinoma: an analysis from the NCCN Oncology Outcomes Database for colorectal cancer. *J Natl Compr Canc* 2014;12: 1123-30
3. Shaib WL, Assi R, Shamseddine A, et al. Appendiceal mucinous neoplasms: diagnosis and management. *Oncologist* 2017; 22:1107-16
4. Saphiro JF, Chase JL, Wolff RA, et al. Modern s. 316-22 Systemic chemotherapy in surgically unresectable neoplasms of appendiceal origin. *Cancer* 2010; 116
5. Jacquet P, Sugarbaker PH. Clinical research methodologies in diagnosis and staging of patients with peritoneal carcinomatosis. *Cancer Treat Res* 1996; 82: 359-74
6. Carr NJ, Sobin LH. Adenocarcinoma of the appendix. In : Bosman FT, Carneiro F, Hruban RH, Theise ND, eds. *WHO Classification of tumors of the digestive system*. Lyon, IARC; 2010: 122-125.
7. Farquharson AL, Pranesh N, Witham G, et al. A phase II study evaluating the use of concurrent mitomycin C and capecitabine in patients with advanced unresectable pseudomyxoma peritonei. *British J Cancer* 2008; 99: 591-596.
8. Carr NJ, Cecil TH, Mohamed F, et al. A consensus for

- classification and pathologic reporting of pseudomyxoma peritonei and associated appendiceal neoplasia. *Am J Surg Pathol* 2016; 40: 14-16
9. McCusker ME, Cote TR, Clegg LX, Sobin LH. Primary malignant neoplasms of the appendix: a population-based study from the Surveillance, Epidemiology, and End Results program. *Cancer* 2002; 94: 1973-1998
 10. Turaga KK, Pappas SG, Gamblin T. Importance of histologic subtype in the staging of appendiceal tumors. *Ann Surg Oncol* 2012; 19:1379-85
 11. Blackham AU, Swett K, Eng C, et al. Perioperative systemic chemotherapy for appendiceal mucinous carcinoma peritonei treated with cytoreductive surgery and hyperthermic intraperitoneal chemotherapy. *J Surg Oncol* 2014; 109: 740-5.
 12. Asare EA, Compton CC, Hanna NN, et al. The impact of stage, grade, and mucinous histology on the efficacy of systemic chemotherapy in adenocarcinomas of the appendix: analysis of the National Cancer Data Base. *Cancer* 2016; 122: 213-21
 13. Lieu CH, Lambert LA, Wolff RA, et al. Systemic chemotherapy and surgical cytoreduction for poorly differentiated and signet ring cell adenocarcinomas of the appendix. *Ann Oncol* 2012;23: 652-658
 14. Sugarbaker PH, Bijelic L, Chang D, Yoo D. Neoadjuvant FOLFOX chemotherapy in 34 consecutive patients with mucinous peritoneal carcinomatosis of appendiceal origin. *J Surg Oncol* 2010; 102: 576-81
 15. Sahib WL, Martin LK, Choi M, et al. Hyperthermic intraperitoneal chemotherapy following cytoreductive surgery improves outcome in patients with primary appendiceal mucinous adenocarcinoma: a pooled analysis from three tertiary care centers. *The Oncologist* 2015; 20:907-914
 16. Kitai T. Pulmonary metastasis from pseudomyxoma peritonei. *Gastroenterol Res Pract* 2012; doi: 10.1155/2012/690256
 17. Xu L, Burke A. Pulmonary metastasis from a low grade mucinous appendiceal neoplasm. *Pathology* 2013; 45: 185-88